

Ocular complications of acoustic neuroma surgery

M G Mulhern, P M Aduriz-Lorenzo, D Rawluk, L Viani, P Eustace, P Logan

Abstract

Aim—To analyse the risk factors involved in the development of ocular complications after acoustic neuroma resection, in particular corneal complications and visual loss, and to identify measures that may reduce these.

Methods—62 patients who underwent surgery for acoustic neuroma had a standardised ophthalmic examination and retrospective case note review.

Results—At final review (mean 37.6 months), although 38 patients reported ocular symptoms, only 22% saw 6/12 or worse. Patients with hypoaesthetic corneas had a higher incidence of corneal pathology (79%) than those with normal sensation (39%). Lagophthalmos increased the incidence of corneal pathology (to 80%); in those with normal closure, the incidence was only 46%. 20 patients required at least one ophthalmic surgical procedure.

Conclusions—After acoustic neuroma resection patients place a considerable burden on the ophthalmologist. Immediate referral postoperatively, and frequent review of those with abnormal sensation may reduce the severity of long term ocular complications.

(Br J Ophthalmol 1999;83:1389-1392)

An acoustic neuroma is a benign tumour derived from the Schwann cells of the vestibulocochlear nerve sheath. The vestibular portion of the nerve arises within the internal auditory meatus, and it is here that the tumour occurs most often. Lesions which produce symptoms do so by distortion of the 8th nerve complex or by displacement of the adjacent brainstem.

The ophthalmic sequelae of tumour resection can ultimately lead to a dry exposed anaesthetic eye, which may (i) require lifelong supplementation with lubricants, (ii) undergo recurrent episode of neurotrophic ulceration, or (iii) painlessly progress onto corneal perforation and iris prolapse. This study seeks to quantify the ophthalmic complications (corneal and visual), highlight the "at risk" groups, and outline the management modalities required after acoustic neuroma resection.

Patients and methods

The case notes of patients undergoing surgery for acoustic neuroma between 1988 and 1997 were obtained. Details of their ophthalmic history were noted. To determine their symptoms, patients were asked "What is the one major complaint with your eye now?" The results of a

neuro-ophthalmic examination were recorded on a standardised form; this included best corrected visual acuity (BCVA), facial nerve function, blink reflex (graded as normal, delayed, or absent); presence or absence of lagophthalmos, ectropion, brow ptosis, and lash ptosis. Corneal sensation was graded as normal, decreased, or absent after being tested with a wisp of cotton. The cornea was examined to determine the incidence of punctate epithelial erosions (PEE), ulceration, scarring, thinning, and corneal neovascularisation.

Patients' notes were reviewed and details regarding any of the following therapeutic interventions noted—tarsorrhaphy, repair of paralytic ectropion, punctal occlusion, brow suspension, gold weight implantation, insertion of lid springs, injection of botulinum toxin into the upper lid, and penetrating keratoplasty. It was determined if they had facial physiotherapy or electrical stimulation of the facial muscles, and if they were still using ocular lubricants. Finally, the clinical findings at each visit were summarised, and the timing of the first postoperative visit was noted.

Results

BASELINE PATIENT FEATURES

The records of 62 patients were available. All these patients were fully assessed for study purposes by an ophthalmologist. The mean follow up was 3 years 1.6 months.

In this study patients were classified as belonging to one of three different groups depending on how soon they were referred to an ophthalmologist: group 1 patients (n = 31) were referred in the first postoperative week, group 2 patients (n = 13) were referred at some time after the first week, and group 3 patients (n = 18) were not referred. Therefore, this latter group was only seen at the research review.

OPHTHALMIC HISTORY

No patient had any pre-existing ophthalmic condition.

PATIENT SYMPTOMATOLOGY

At the research review, 57 of the patients were questioned to determine if they had any ophthalmic symptoms after surgery; 19 (33.4%) were asymptomatic, while the following symptoms were reported by the others—dryness (33.4%), crocodile tears (7%), epiphora (5.3%), poor acuity (3.5%), reduced visual field secondary to brow ptosis (1.7%) and secondary to tarsorrhaphy (1.7%), aberrant regeneration induced lid closure on yawning (1.7%), and miscellaneous (12.3%).

FACIAL NERVE PALSY

All the patients reviewed by the ophthalmic department postoperatively (n = 44) (groups 1

Department of
Ophthalmology,
Beaumont Hospital,
Dublin, Ireland

M G Mulhern
P M Aduriz-Lorenzo
P Eustace
P Logan

Department of
Neurosurgery
D Rawluk

Department of
Otolaryngology
L Viani

Correspondence to:
Mark Mulhern, University of
Toronto, Department of
Ophthalmology, The
Toronto Hospital, Western
Division, 399 Bathurst
Street, EC7-009, Toronto,
Ontario, Canada M5B 2H3

Accepted for publication
25 August 1999

Table 1 Characteristics of the early, late, and non-referral groups

	Group 1 (n=31)	Group 2 (n=13)	Group 3 (n=18)
Sensation			
decreased	65%	54%	17%
normal	35%	46%	83%
Lagophthalmos			
yes	52%	31%	0%
no	48%	69%	100%
Corneal PEE			
yes	74%	69%	22%
no	26%	31%	78%
BCVA			
6/6 or better	81%	54%	100%
6/9	7%	15%	
6/12	3%	23%	
6/18			
6/24	3%		
6/36			
6/60			
CF	3%		
HM	3%		
NPL		8%	
Number of procedures			
0	64%	46%	100%
1	26%	46%	0%
2	3%	8%	0%
3 or more	7%	0%	0%

BCVA = best corrected visual acuity; CF = counting fingers; HM = hand movements; NPL = no perception of light; PEE = punctate epithelial erosions.

and 2) were noted to have a 7th nerve palsy, and 32 (72%) of these had lagophthalmos. At the research review, 41 (66%) of the 62 patients reviewed had some evidence of facial palsy, and 20 (32%) (all members of group 1 or 2) still had some evidence of lagophthalmos (see Table 1).

At the research review, more patients with lagophthalmos had 6/12 or worse acuity (35%), than those without lagophthalmos (only 2%). The presence of lagophthalmos correlated with the amount of corneal pathology; 80% had PEE, 30% had an ulcer at some stage postoperatively, 15% had a corneal perforation, 25% had corneal scars, 20% had corneal neovascularisation, 10% required corneal grafting, 5% had Salzmann's nodular dystrophy, and 5% were eviscerated; whereas, in the group without lagophthalmos, no corneal

pathology was evident in 54% and 46% had PEE only. Long term sequelae of 7th nerve palsy included brow ptosis in 32.7%, lash ptosis in 42.3%, and paralytic ectropion in 6.7%. At the research review, the blink reflex was classified as normal in 43%, delayed in 39%, and absent in 18%.

CORNEAL SENSATION

Corneal sensation at the research follow up was decreased in 41.6%, absent in 8.4%, and normal in 50%. There was a correlation between corneal sensation at final review and BCVA. BCVA was 6/12 or worse in 3.3% of the group with normal sensation but rising to 12.5% in the group with decreased sensation, and higher still, 50%, in the group with absent sensation. Reducing corneal sensation also correlated with a reduction in the number of patients with normal corneas. Over 50% of the patients in groups 1 and 2 had abnormal sensation (see Table 1) and corneal PEE were present in over 60% of the patients in both groups; in the non-referral group (group 3), sensation was poor in 17% and PEE were present in just 22%.

VISUAL ACUITY

The BCVA at the research review was compared with the first recorded BCVA immediately postoperatively (see Fig 1) (the eviscerated patients' BCVA was recorded as NPL). At acuity levels 6/4–6/6, the percentage of patients increased from 26% immediately postoperatively to 79% at the research review. Only at the worst acuity levels (HM and NPL) was there an increase in numbers, both showed a rise from 0% to 1.6% (one case).

We determined how many patients had a drop in acuity by comparing their BCVA at their first and final visits. Of the 42 patients whose vision was documented immediately postoperatively only five (12%) had a "significant" drop in visual acuity (that is, a final BCVA of less than 6/6). These patients' details are set out in Table 2.

CORNEAL PATHOLOGY

Table 1 demonstrates that although group 2 had less lagophthalmos and better corneal sensation than group 1, the incidence of corneal changes (PEE) (69%) at the research review was almost the same as in group 1 (74%). In contrast, group 3 had a low incidence of reduced corneal sensation (17%), a zero incidence of lagophthalmos, and a correspondingly low incidence of corneal PEE (22%).

Although no case had corneal ulceration at final review, the postoperative management was sometimes complicated by ulceration arising from infection, exposure, corneal dehydration, corneal anaesthesia, or a combination of these factors. Two patients had dendritic ulcers, one later perforated and required corneal grafting. Three patients had ulcers which became bacterially infected, one required a graft and another was eviscerated.

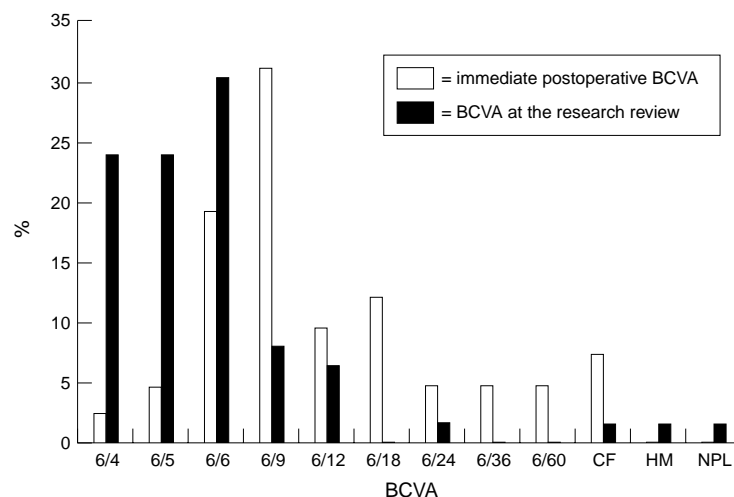


Figure 1 Immediate postoperative BCVA versus BCVA at the research review. BCVA = best corrected visual acuity; CF = counting fingers; HM = hand movements; NPL = no perception of light; PEE = punctate epithelial erosions.

Table 2 An analysis of the cases which had a "significant" reduction in BCVA

Acuity drop	House-Brachman score	Lagophthalmos	Corneal sensation	Corneal finding	Treatment
Case 1 CF→NPL	6	Yes	Decreased	Perforated ulcer	Eviscerated
Case 2 6/36→HM	6	Yes	Absent	Perforated ulcer	Tarsorrhaphy Gold weight Corneal graft Cataract extraction
Case 3 6/12→CF	5	Yes	Decreased	Ulcer →scar	Total tarsorrhaphy Lid spring
Case 4 6/6→6/24	6	Yes	Absent	Perforated	Tarsorrhaphy Corneal graft Cataract extraction
Case 5 6/6→6/12	6	Yes	Decreased	PEE	Tarsorrhaphy

TREATMENT

Only group 1 and 2 patients required therapeutic procedures. No group 3 patient required any procedure. Table 1 demonstrates that group 2 required more surgical procedures than group 1, and that a higher percentage of these patients required multiple procedures.

Twenty of the 62 cases (32%) in our series required at least one surgical intervention, the procedures performed were tarsorrhaphy (32.25%), paralytic ectropion repair (3.2%), brow suspension (3.2%), upper lid botulinum injection (3.2%), penetrating keratoplasty (3.2%), cataract extraction (3.2%), gold weight insertion (1.6%), lid spring insertion (1.6%), and evisceration (1.6%).

Discussion

After acoustic neuroma resection, the patients' ophthalmic status is aggravated; subjectively, 38 cases had symptoms postoperatively and, objectively, 23 remained on long term ocular lubricants, 20 required tarsorrhaphy, and three cases had perforated corneas (two of these required penetrating keratoplasty, and one was eviscerated). However, despite the serious corneal problems encountered, and the number of patients requiring at least one surgical intervention (20), only 12% had a significant reduction in BCVA.

The spectrum of corneal pathology ranged from PEE, to cases with corneal neovascularisation and scarring, to cases which perforated and required penetrating keratoplasty. In one of these latter cases, corneal disease was so severe that the graft developed a descemetocele. Recurrent episodes of ulceration often began as a consequence of hypoaesthesia and poor tear film. In some cases these ulcers became bacterially infected. The presence of hypoaesthesia and/or lagophthalmos increased the risk/incidence and severity of corneal pathology. Hypoaesthesia was the greatest risk factor for the development of corneal pathology and it reduced the number of normal corneas from 61% to 21%—more importantly, *no patient* with absent corneal sensation had a

normal cornea. Lagophthalmos reduced the number of normal corneas from 54% to 20%.

Delaying the first postoperative visit can have serious consequences as the cornea may be hypoaesthetic, and patients therefore may not report eye problems. It is important to remember that the patient's ophthalmic status may be at its best immediately after surgery only to deteriorate in the following weeks. However, there may also be a later improvement if facial nerve function improves or if the correct therapy is instituted. The "delayed" referral group (group 2) highlighted these facts (see Table 1); although this group had less lagophthalmos and less sensation deficits than group 1, the incidence of corneal problems was almost the same as group 1. Patients in group 2 required more procedures than their group 1 counterparts, and the patients who had corneal grafts and evisceration all belonged to group 2. Also, their visual outcome was worse, a lower percentage having a BCVA of 6/6 or better. These findings suggest that early referral leads to a better outcome. Of the 62 cases reviewed 18 (25%) were never referred to the ophthalmic department. These patients were correctly identified as low risk patients by the neurosurgical/otolaryngological departments, based on their House-Brachman score and therefore not referred; however, as seen in Table 1, 17% had sensation deficits and 22% had PEE. Therefore, this subset of patients must be categorised as "at risk" from an ophthalmic viewpoint. The reason for this discrepancy is that the House-Brachman index does not take corneal sensation or tear secretion into account.

Only five patients (12%) showed a significant reduction in BCVA (Table 2), all five had the combination of exposure and reduced corneal sensation; therefore, such cases must be watched especially closely, as they represent the other "at risk" subset. Figure 1 emphasises the eventual shift of the majority of patients to better acuity levels with time, either because of active management by the ophthalmologist or improving facial nerve function (from 71% to 32%).

The management of facial palsy begins intraoperatively, where attempts are made to minimise trauma to the nerve. A recent innovation to reduce neuronal injury is to monitor facial nerve function intraoperatively.¹ The continuous auditory feedback provided informs the surgeon if the facial nerve is being compromised; this allows the surgeon to adjust his approach. Ebersold *et al* recommended prophylactic tarsorrhaphy if the monitor's amplitude dropped by 50%.²

Postoperative management depends on the presence or absence of lagophthalmos. Depending on the state of the facial nerve at the end of surgery, the patients may or may not demonstrate an improvement in facial function with time. Rehabilitation may be aided by facial physiotherapy and trophic nerve stimulation; the latter entails using a waveform to stimulate the motor end plate, which theoretically maintains muscle metabolism and prevents denervation hypersensitivity.

Wesley has described the surgical techniques to correct the lid sequelae of facial palsy.³ In our series (Table 2), tarsorrhaphy was the commonest procedure performed, followed by paralytic ectropion repair, brow suspension, gold weight insertion, and upper lid spring insertion. The blink reflex was abnormal (delayed or absent) in 23 patients; however, only a few patients required either gold weight insertion (to augment the blink reflex), or lid springs (for frank lagophthalmos). Nakamori *et al* recently suggested that blinking is controlled by ocular surface conditions (such as dry eye)⁴; however, a compensatory increase in blinking may not be possible in these patients, because of orbicularis oculi weakness.

Patients with hypoaesthetic corneas must monitor their visual acuity in order to enhance the chances of detecting impending neurotrophic ulceration. "At risk" patients should be kept on lifelong lubricants, and it is advisable to leave any tarsorrhaphy in situ. Patients with neurotrophic ulceration are difficult to manage, often requiring hospital admission, topical steroid administration, frequent instillation of lubricants, and/or tarsorrhaphy or enlargement of any existing tarsorrhaphy.

Facial nerve palsy also results in cosmetic sequelae due to atrophy of the facial muscles (evident as loss of muscle bulk) and loss of

muscle tone (for example brow ptosis). If there is no spontaneous improvement in facial nerve function after about 12 months,⁵ a brow suspension may be useful. In severe cases of facial palsy, the patient may require not just periocular, but complete, facial reanimation using nerve anastomosis or muscle transposition.

In conclusion, patients after acoustic neuroma resection are labour intensive; 32% required at least one surgical procedure. They may require lifelong therapy—for example, lubricants, tarsorrhaphy, or graft management. The patients most at risk of losing vision are those whose referral is delayed and those with combined lid closure and sensation deficits.

- 1 Leonetti JP, Matz GJ, Smith PG, *et al*. Facial nerve monitoring in otologic surgery: clinical indications and intraoperative techniques. *Ann Otol Rhinol Laryngol* 1990;**99**:911–18.
- 2 Ebersold MJ, Harner SG, Beatty CW, *et al*. Current results of retrosigmoid approach to acoustic neuroma. *J Neurosurg* 1992;**76**:901–9.
- 3 Wesley RE. Diagnosis and management of facial nerve palsy. In: Stewart WB, ed. *Surgery of the eyelid, orbit and lacrimal system*. Vol 2, chapter 19. San Francisco: American Academy Ophthalmology, 1994.
- 4 Nakamori K, Odawara M, Nakajima T, *et al*. Blinking is controlled primarily by ocular surface conditions. *Am J Ophthalmol* 1997;**124**:24–30.
- 5 Hoffman WY. Reanimation of the paralysed face. *Otolaryngol Clin N Am* 1992;**25**:649–67.