

## Editorial

First descriptions of tuberous sclerosis by  
Désiré-Magloire Bourneville (1840–1909)

Tuberous sclerosis complex (TSC) is a genetically inherited neurocutaneous disorder that may affect many organ systems, including brain, skin, eyes, heart, lungs, liver, and kidneys.<sup>1</sup> TSC is clinically characterized by benign tumors in multiple organs and typical skin lesions (hypopigmented macules and angiofibromas, previously termed adenoma sebaceum). The cerebral lesions typically encountered in approximately 90% of the children with TSC<sup>2</sup> are cortical tubers (glioneuronal hamartomas), subependymal nodules and subependymal giant cell astrocytomas. Hamartomas may also involve other organs, such as the heart (cardiac rhabdomyomas) and the kidneys (renal angiomyolipomas).<sup>1</sup> Most patients have epilepsy, are often drug-resistant, and one-half or more have cognitive deficits and learning disabilities.<sup>3</sup>

The first detailed descriptions of clinical and neuropathological features of TSC were made by Désiré-Magloire Bourneville (1840–1909), although the typical skin lesions were depicted in a dermatological atlas illustrated by the French physician Pierre François Rayer (1793–1867) in 1835.<sup>4</sup> Furthermore, the initial description of cardiac rhabdomyomas and cortical tubers were made in 1862 by Friedrich Daniel von Recklinghausen, during a talk given at the Obstetrical Society of Berlin.<sup>5</sup> Presenting the pathologic findings of a newborn who died shortly after birth, von Recklinghausen described cardiac tumors, which he termed “Myomen” (“myomata”), and mentioned “scleroses” in the brain.<sup>5</sup> However, it was Bourneville who deserves credit for describing in detail this condition, giving it the name which is still in use.

Bourneville was born on October 21, 1840 as the son of a landowner.<sup>6–8</sup> After studying in Paris, where he received his doctorate in 1870, was appointed *Médecin des services d'aliénés* at the Bicêtre Hospital in Paris, where he worked from 1879 until his retirement in 1905. He played an active role during the Paris Commune in 1871, when he saved many of his patients whom had been condemned to death for political reasons during the uprisings.<sup>9</sup> With regard to his editorial activities, in 1873 he founded the scientific journal “Le Progrès Médical”, where he published several articles, and in 1880 the “Archives de Neurologie” (under the patronage of Charcot). From 1876 to 1880 he published, together with P. Regnard, the famous *Iconographie*

*photographique de la Salpêtrière*. Besides tuberous sclerosis, he published several essays and articles on cretinism, mongolism, and myxedema.

Our aim is to further elucidate the contribution of this neuroscientist in the history of neuropathology in the 19th Century, by reporting and commenting on the first descriptions of patients with TSC provided by Bourneville himself.

On May 7, 1879, Bourneville performed an autopsy on a 15-year-old woman, whose name was L. Marie. The results of the post-mortem examination were reported in 1880.<sup>10</sup>

At the age of 3, Marie had been admitted to the Paris Hospital of *La Salpêtrière*; she had a right spastic hemiplegia, a severe mental retardation (*idiotie*, idiocy) and had experienced focal seizures and episodes of status epilepticus starting at the age of 2.

A general examination performed in March 1879 reported the first description of the skin abnormalities (likely angiofibromas) that later would have been recognized as typical of TSC. Marie presented with “a confluent vesicular-papular eruption of the nose, cheeks, forehead” and “many small molluscums [i.e., skin tags of the molluscum pendulum type] on the neck and on the parts of the neck, which is short.”

Bourneville did not relate the skin lesions to the TSC, probably because he focused his description on the cerebral pathology, and also in his subsequent clinical descriptions he made no mention of them.<sup>11</sup> The typical facial angiofibromas were described in detail some years later by Félix Balzer (1849–1929) and Pierre-Eugène Ménétrier (1859–1935) in France<sup>12</sup> and by John James Pringle (1855–1922) in Great Britain.<sup>13</sup> They were called, rather inappropriately, *adenoma sebaceum*, and were reported in association with seizures and mental retardation, sometimes found in several members of the same family. For many years, the triad described by the German neurologist Heinrich Vogt (1875–1957) consisting of seizures, mental handicap, and *adenoma sebaceum* was used to clinically diagnose TSC.<sup>14</sup>

Her focal seizures, characterized by clonic jerks of the right limbs with Jacksonian march,<sup>15</sup> were described in detail (Supplementary material, File S1, text 1). The post-mortem examination revealed several sclerotic areas

involving cerebral convolutions (File S1, Fig. 1; File S1, text 2). To describe the peculiarity of this cerebral pathology, Bourneville coined the term tuberous sclerosis (*“Sclérose tubéreuse des circonvolutions cérébrales”*, Tuberous Sclerosis of the Cerebral Convolutions).

Bourneville emphasized that the sclerotic areas found in the brain of this patient showed peculiar features which were not consistent with those previously reported in multiple sclerosis (*sclérose en plaques*), a neuropathological entity which had been first described by Jean-Martin Charcot (1825–1893) in 1865<sup>16</sup> (File S1, text 3). As a pupil of Charcot, Bourneville knew very well the neuropathological features of multiple sclerosis, to which he had

devoted a monograph (*De la sclérose en plaques disséminées*) written together with Léon Guérard (1840–?) and published in 1869, as an extension of Guérard’s thesis presented on April 26, 1869 under the direction of Alfred Vulpian (1826–1887).<sup>17</sup>

Providing an outstanding example of neuroclinical correlation, Bourneville attributed the origin of the focal clonic seizures involving the right limbs to a large tuber in the left ascending frontal and parietal convolutions (File S1, text 4). Furthermore, the examination of kidneys showed kidney nodules (renal angiomyolipomas; (File S1, text 5)), which Bourneville did not relate with the cerebral sclerotic areas. Interestingly, also in his subsequent clinical descriptions he failed to recognize kidney abnormalities as typical characteristics of TSC.<sup>11,18</sup> The first one to note that kidney tumors were part of the TSC was Heinrich Vogt in 1908.<sup>14</sup>

A year later (1881), Bourneville and Edouard Brissaud (1852–1909)<sup>19</sup> described the post-mortem findings of a 4-year-old boy, Georges, with severe mental retardation, cardiac murmur and congenic cyanotic heart disease (*maladie bleue*), and right-sided paresis, who stopped eating and drinking until he died.<sup>18</sup>

Also in this case, the kidneys showed kidney nodules (File S1, text 6). The cerebral pathology revealed striking similarities with that of Marie’s (File S1, Fig. 2).

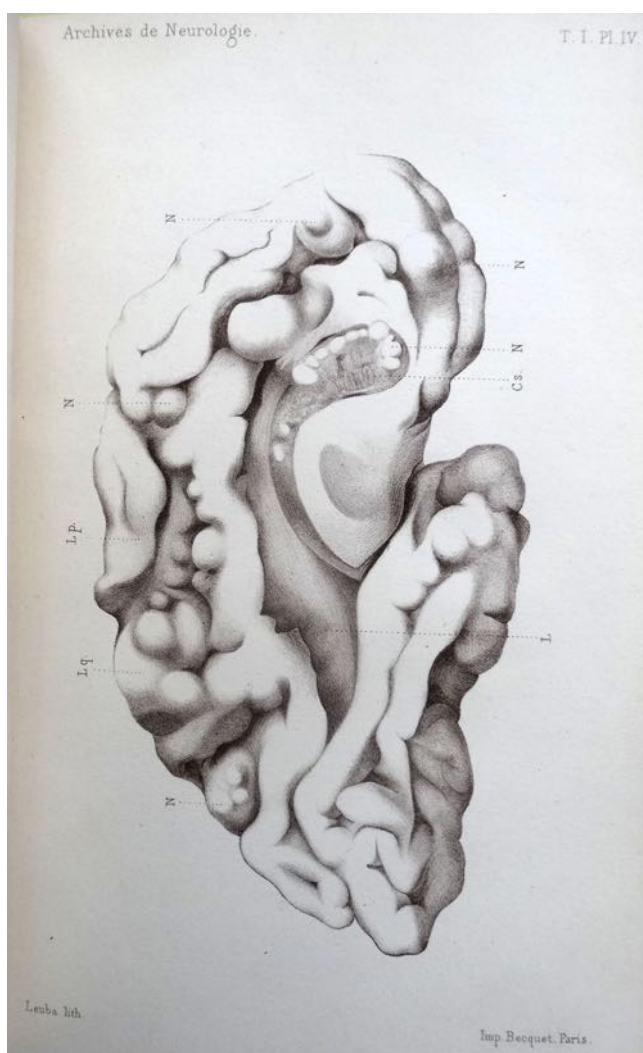
Of note, the small sclerotic tumors in correspondence with the lateral walls of the ventricles was the first description of what would have been further defined as subependymal nodules (File S1, text 7).

This second patient gave Bourneville the opportunity to extensively discuss his findings (File S1, text 8).

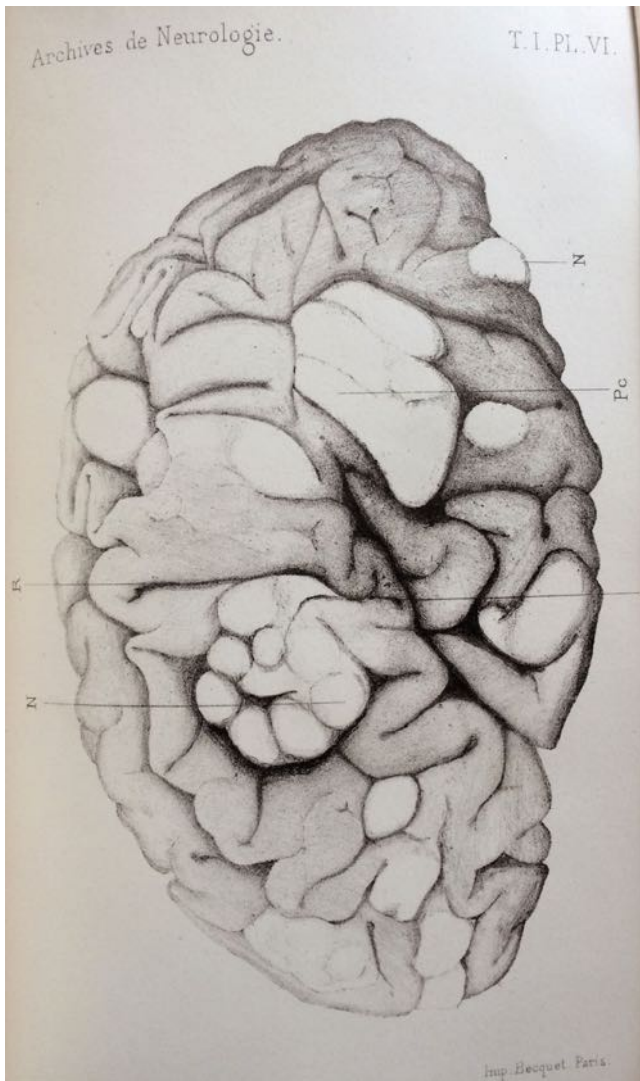
It must be first noticed that the name of Brissaud, associated with that of Bourneville in the second part of this seminal paper, is explained by the fact that Brissaud is the only one who archived all the anatomopathological studies. Thus, this syndrome could have been called “sclérose tubéreuse de Bourneville-Brissaud”. In the above passage, Bourneville and Brissaud emphasize the peculiarities of the pathological findings reported, concluding that tuberous sclerosis should be considered as a specific neuropathological condition. Interestingly, in this second report he indifferently uses the name “*encéphalite tubéreuse*” beside the term “*Sclérose tubéreuse des circonvolutions cérébrales*” he had coined when describing the cerebral pathology in Marie’s case.

More specifically, Bourneville and Brissaud highlighted the differences with cerebral findings typical of multiple sclerosis and meningoencephalitis of general paralysis.

Bourneville and Brissaud suggested that the novel neuropathological entity first described should not necessarily be classified among cerebral hypertrophies (File S1, text



**Fig. 1** Internal surface of left hemisphere of L. Marie, the first patient affected by tuberous sclerosis described by Bourneville. The letter “N” indicates the sclerotic areas involving cerebral convolutions. This original drawing, made by Brissaud, was reported in: Bourneville DM. Contribution à l’étude de l’idiotie. Arch Neurol (Paris) 1880–1881;1 (1):69–90 [Dr. Walusinski’s personal collection].



**Fig. 2** Internal surface of left hemisphere of Georges, the second patient affected by tuberous sclerosis described by Bourneville. This original drawing was reported in: Bourneville DM, Brissaud E. Encéphalite ou sclérose tubéreuse des circonvolutions cérébrales. Arch Neurol (Paris) 1881; 1: 390–410. [Dr. Walusinski's personal collection]. Bourneville described these macroscopic findings as follows: “Internal side. we note: A group of sclerotic islands interesting the origin of the first frontal convolution and the convolution of the corpus callosum; some islands on the other regions of the first frontal, and on the convolution of the corpus callosum. The paracentral lobe, quite bulky, has a small island up and forward. The square lobe [the cuneus] is normal. Finally, on the temporo-occipital convolutions, one sees a rather large sclerous islet.” [Face interne. Notons: un groupe d’îlots scléreux intéressant l’origine de la première circonvolution frontale et de la circonvolution du corps calleux; quelques îlots sur les autres régions de la première frontale, et sur la circonvolution du corps calleux. Le lobe paracentral, assez volumineux, présente un petit îlot en haut et en avant. Le lobe carré est normal. Enfin, sur les circonvolutions temporo-occipitales, on voit un îlot scléreux assez gros.]

9). Bourneville and Brissaud went on to describe the involvement of the gray matter, suggesting that – with regard to this feature – this condition may be called

“tuberous polioencephalitis” (File S1, text 10). However, Bourneville and Brissaud were not able to identify any specific histological alteration which would enable them to shed light on the pathogenesis of tuberous sclerosis (File S1, text 11).

Brissaud analyzed fragments of brain tissue which had been hardened using ammonium dichromate and stained with picocarmine, which was a stain for tissue sections made by mixing solutions of carmine and picric acid.<sup>20</sup> It is very likely that the rudimentary histological colorations used prevented Bourneville from describing in detail the histological peculiarities of tuberous sclerosis. It was only with the histopathological studies made in 1901 by the Italian Giovanni Battista Pellizzi (1865–1950) that the dysplastic nature of the cerebral lesions (disordered cortical architecture, embryonic appearance of the abnormal cells, defects of myelination, and heterotopias) was recognized and characterized in detail.<sup>21</sup> However, Pellizzi could benefit from the silver staining technique introduced by Camillo Golgi (1843–1926) in 1873,<sup>22</sup> and which at the time of the first descriptions made by Bourneville was not popular among neuroscientists.

However, Brissaud was able to recognize the disorganized areas of the cortex containing neuronal and glial elements, responsible for the hardened consistency of the tubers (File S1, text 12).

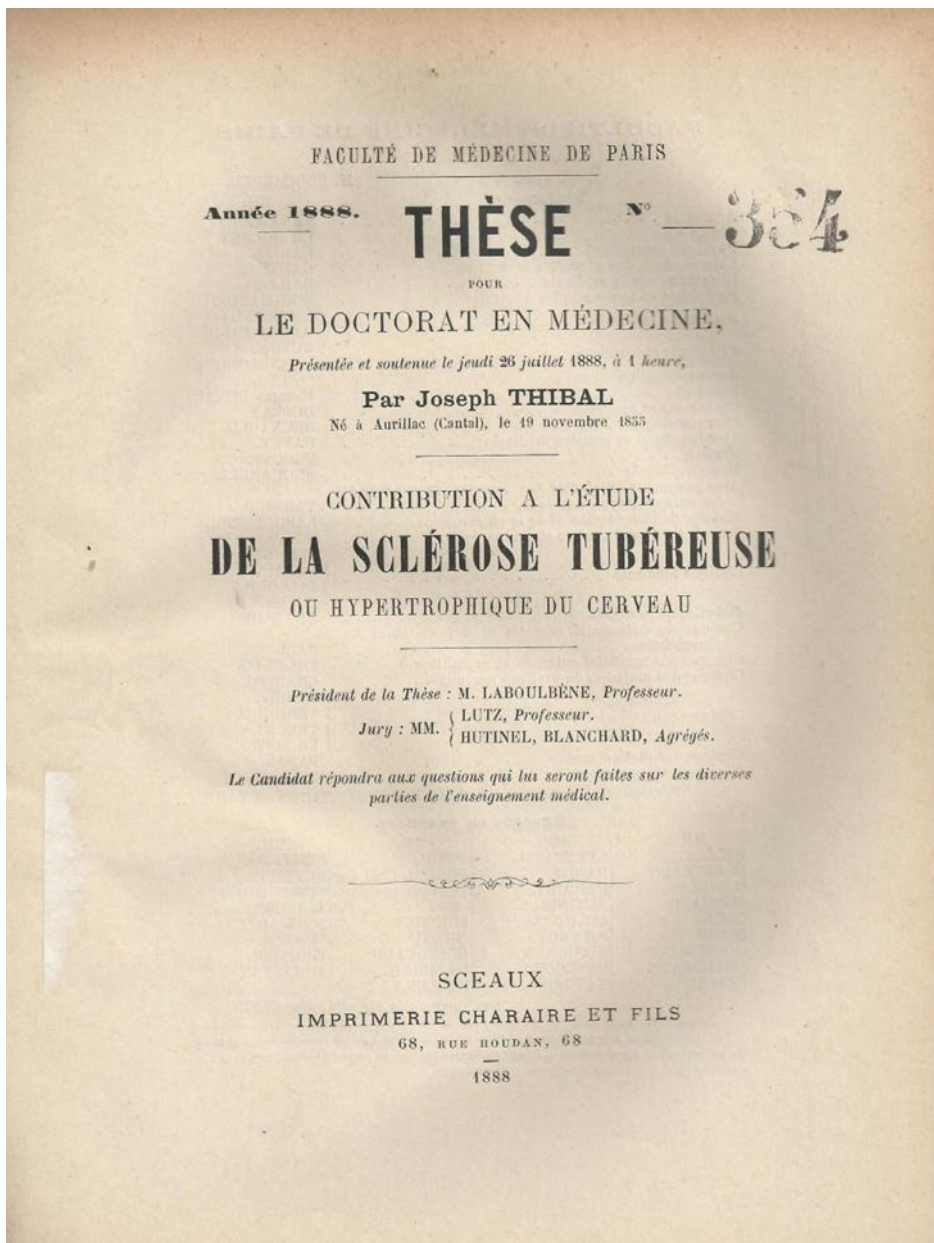
Thus, Bourneville and Brissaud concluded that (File S1, text 13):

*“meningitis, a nearly constant pathogenic factor in most idiocy and epileptiform diseases, cannot be called into question here. It is rather a chronic inflammatory process, very slow, whose starting point lies in the neuroglia of the cortical gray matter, but whose location in the most superficial parts of the brain is due to causes that still escape us completely.”*

In 1888, Bourneville supervised the doctoral thesis of his pupil, Joseph Thibal (1855–?), adding a personal new case and reporting another published by a German author, Oscar Brückner in 1882<sup>23,24</sup> (File S1, Fig. 3). Overall, between 1880 and 1898, Bourneville reported a total of 10 patients with neuropathological findings consistent with a diagnosis of tuberous sclerosis. The main clinical features of these patients were summarized in a table, included in a collection of clinical cases of severe mental retardation (idiocy)<sup>11</sup> (File S1, text 14). Here, Bourneville reported that

*“the idiocy symptomatic of tuberous sclerosis is often clinically complicated with epilepsy (nine times out of ten); that epilepsy is manifested seven times out of nine by seizure and vertigo, once by access once by vertigo.”*





**Fig. 3** Frontispiece of the doctoral thesis (1888) of Joseph Thibal (1855–?) who was one of Bourneville’s pupils. In this thesis a personal new case of tuberous sclerosis and an additional one published by the German author Oscar Brückner in 1882 have been described. Thibal J. Contribution à l’étude de la sclérose tubéreuse ou hypertrophique du cerveau. Thèse Paris n°354. Imp. Charaire. 1888. [Dr. Walusinski’s personal collection].


*From the anatomopathological point of view, we see [...] that tuberous sclerosis is associated with meningo-encephalitis five times out of ten.”*

Interestingly, in this passage Bourneville uses the terminology introduced in 1854 by Louis Jean François Delasiauve (1804–1893). Delasiauve had differentiated four types of seizures, which were ranked in order of increased severity: *absences* for petit mal, *vertiges* for vertiginous attacks (a term possibly referring to focal seizures with impaired awareness), *accès intermédiaires* or *chutes* (i.e., focal seizures with secondary generalization), and *chutes* or *accès complets* for generalized convulsive seizures.<sup>25</sup>

This case series emphasizes the high prevalence of epilepsy in TSC, which affects approximately 85% of patients,<sup>1</sup> usually beginning in the first year of life and in most patients in the first few months.

In his clinical descriptions, Bourneville failed to recognize skin and kidney lesions as part of what would have been later recognized as a multisystem disorder that may affect any human organ, without being confined to the brain alone. He probably did not recognize that he was confronted with a new syndrome, and not just with a new neuropathological condition. Although it took a period of time spanning 160 years to eventually develop the concept of TSC, the first neuropathological observations made by Bourneville retain their validity.

The contribution provided by Bourneville and Brissaud in describing the neuropathological features of tuberous sclerosis, differentiating it from other conditions such as multiple sclerosis, and in emphasizing its association with epilepsy and mental handicap, is invaluable. He therefore rightly deserves to have his name attached to the disease worldwide known as tuberous sclerosis (Bourneville's syndrome).

Francesco Brigo,<sup>1,2</sup>  Simona Lattanzi,<sup>3</sup> Eugen Trinko,<sup>4,5,6</sup> Raffaele Nardone,<sup>2,4</sup> Nicola L. Bragazzi,<sup>7</sup> Martino Ruggieri,<sup>8</sup> Mariano Martini<sup>9,10,11\*</sup> and Olivier Walusinski<sup>12\*</sup>

<sup>1</sup>Department of Neurosciences, Biomedicine and Movement Sciences, University of Verona, Verona, <sup>2</sup>Division of Neurology, “Franz Tappeiner” Hospital, Merano, <sup>3</sup>Neurological Clinic, Department of Experimental and Clinical Medicine, Marche Polytechnic University, Ancona, <sup>4</sup>Department of Health Sciences (DISSAL), School of Public Health, <sup>11</sup>Unesco Chair “Anthropology of Health-Biosphere and Healing System”, University of Genoa, <sup>10</sup>Department of Health Sciences, Section of Medical History and Ethics, University of Genoa, Genoa, <sup>8</sup>Unit of Rare Diseases of the Nervous System in Childhood, Department of Clinical and Experimental Medicine, Section of Pediatrics and Child Neuropsychiatry, AOU “Policlinico-Vittorio Emanuele”, University of Catania, <sup>9</sup>Department of Clinical and Experimental Medicine, Section of History of Medicine, University of Catania, Catania, Italy, <sup>4</sup>Department of Neurology, Christian Doppler Klinik, Paracelsus Medical University, <sup>5</sup>Center for Cognitive Neuroscience, Salzburg, <sup>6</sup>Public Health, Health Services Research and HTA, University for Health Sciences, Medical Informatics and Technology, Hall i.T, Austria and <sup>12</sup>Family Physician, Brou, France

\*These authors contributed equally

## REFERENCES

- Curatolo P, Bombardieri R, Jozwiak S. Tuberous sclerosis. *Lancet* 2008; **372**: 657–668.
- Mizuguchi M, Takashima S. Neuropathology of tuberous sclerosis. *Brain Dev* 2001; **23**: 508–515.
- Yates JR, Maclean C, Higgins JN *et al*. Tuberous sclerosis 2000 study group. The tuberous sclerosis 2000 study: Presentation, initial assessments and implications for diagnosis and management. *Arch Dis Child* 2011; **96**: 1020–1025.
- Rayer PFO. *Traité Théorique et Pratique des Maladies de la Peau*, 2nd edn. Paris: J.-B. Baillière, 1835.
- von Recklinghausen F. Ein Herz von einem Neugeborene welches mehrere theils nach aussen, theils nach den Hohlen promimirende Tumoren (Myomen) trug. *Monatschr Geburtsheilkd* 1862; **20**: 1–2.
- Poirier J, Signoret JL. Historical note: Désiré-Magloire Bourneville (1840–1909). *Rev Neurol (Paris)* 1991; **147**: 705.
- Gómez MR. History of the tuberous sclerosis complex. *Brain Dev* 1995; **17** (Suppl): 55–57.
- Gateaux-Mennecier J. Bourneville, humanist and reformer. *Rev Prat* 2002; **52**: 1517–1521.
- Walusinski O. Neurology and neurologists during the Franco-Prussian War (1870–1871). *Front Neurol Neurosci* 2016; **38**: 77–92.
- Bourneville DM. Contribution à l'étude de l'idiotie. *Arch Neurol (Paris)* 1880–1881; **1**: 69–90.
- Bourneville DM. Idiotie symptomatique de la sclérose tubéreuse ou hypertrophique. *Le Progrès Médical (Paris) (série III)* 1899; **10**: 241–248.
- Balzer F, Menetrier P. Étude sur un cas d'adénomes sébacés de la face et du cuir chevelu. *Arch Physiol Norm Pathol (série III)* 1885; **6**: 564–576.
- Pringle JJ. A case of congenital adenoma sebaceum. *Br J Dermatol* 1890; **2**: 1–14.
- Vogt H. Zur Pathologie und pathologischen Anatomie der verschiedenen Idiotieformen. *Monatsschr Psychiatr Neurol* 1908; **4**: 106–150.
- Jackson JH. Notes on the physiology and pathology of the nervous system. *Med Times Gaz* 1868; **2**: 696.
- Charcot JM. Sclérose du cordons lateraux de la moelle épinière chez une femme hystérique atteinte de contracture permanente des quatre membres. *L'Union Médicale* 1865; **25**: 451–457 467–472.
- Bourneville DM, Guérard L. *De la sclérose en plaques disséminées*. Paris: Delahaye, 1869.
- Bourneville DM, Brissaud E. Contribution à l'étude de l'idiotie. *Arch Neurol (Paris)* 1880–1881; **1**: 391–412.
- Poirier J, Ricou P. Edouard Brissaud (1852–1909), Charcot's favorite pupil. *Hist Sci Med* 2010; **44**: 247–255.
- Jensen V. On picro-carmin. *j* 1921; **2**: 103–104.
- Pellizzi GB. Contributo allo studio dell'idiozia: rivisita sperimentale di freniatria e medicine legate delle alienazioni mentali. *Riv Sper Freniatr* 1901; **27**: 265–269.
- Golgi C. Sulla struttura della sostanza grigia del cervello. *Gazz Med Ita Lombarda* 1873; **33**: 244–246.
- Thibal J. Contribution à l'étude de la sclérose tubéreuse ou hypertrophique du cerveau (Thèse Paris n°354), Imp. Charaire. 1888.
- Brückner O. Über multiple, tuberöse Sklerose der Hirnrinde. *Archiv für Psychiatrie und Nervenheilkunde* 1882; **12**: 550–563.

25. Brigo F, Trinka E, Lattanzi S, Bragazzi NL, Nardone R, Martini M. A brief history of typical absence seizures — Petit mal revisited. *Epilepsy Behav* 2018; **80**: 346–353.

### SUPPORTING INFORMATION

Additional supporting information may be found in the online version of this article at the publisher's website:

**File S1.** Supporting information file.

**Text 1.** Detailed description of Marie's focal seizures.

**Text 2.** Details of Marie's brain post-mortem examination.

**Text 3.** Discussion on the peculiar features of tuberous sclerosis.

**Text 4.** Neuroclinical correlation; Marie's focal clonic seizures involving the right limbs attributed to a large tuber in the left ascending frontal and parietal convolutions.

**Text 5.** Details of Marie's kidney examination.

**Text 6.** Details of Georges' kidney examination.

**Text 7.** Description of subependymal nodules.

**Text 8.** Discussion of neuropathological findings.

**Text 9.** Discussion on tuberous sclerosis and cerebral hypertrophies.

**Text 10.** Discussion on involvement of the gray matter ("tuberous polioencephalitis").

**Text 11.** Discussion on pathogenesis of tuberous sclerosis.

**Text 12.** Histopathological description.

**Text 13.** Pathophysiological considerations.

**Text 14.** Anatomoclinical considerations.